

Efficient Mechanics of PIP Mobilisation Splinting

Judy C Colditz, Consultant in Hand Therapy
Raleigh, USA

The proximal interphalangeal (PIP) joint, a tightly constructed hinge joint, frequently develops limited motion following injury. Mobilisation splints are the most frequently used method of regaining PIP joint motion following isolated PIP injury.

This article reviews a variety of PIP mobilisation splints, which the author has found effective. In addition to discussing the biomechanics of PIP extension and flexion mobilisation splinting, a variety of designs are offered for PIP extension mobilisation and one design for PIP flexion mobilisation. Clinical problems discussed include: PIP extension lag, PIP flexion contracture responsive to stretch (including acute boutonniere), PIP joint contracture unresponsive to stretch, and gaining/maintaining the last few degrees of PIP extension in a resistive contracture as well as isolated PIP flexion mobilisation. For all splints, construction advice and other tips are given for successful use of these designs.

LIMITATIONS OF PIP JOINT MOTION

The proximal interphalangeal (PIP) joint is a tightly constructed hinge joint that has little tolerance for accessory motion. Being relatively unprotected, the PIP joint translates external forces into soft tissue injury. The frequently used, larger, and more powerful extrinsic flexor muscles overwhelm the weaker intrinsic extensors of the PIP joint. The thin, expansive extensor hood tendon has large surface contact with the underlying bone and easily adheres. As the patient attempts to either flex or extend the PIP joint, the more mobile proximal metacarpophalangeal (MP) joint receives the first transmission of force and either hyper-extends or hyper-flexes before the force is transmitted to the more resistive PIP joint.

Immediately following trauma the PIP joint will be swollen (joint effusion). The thinner dorsal part of the capsule allows one to palpate the fluctuant thickened joint oedema. The increased internal pressure within the joint provides resistance to full PIP motion. If seen acutely, such a joint needs immobilisation in full extension with compression to the digit to decrease the post-traumatic oedema in and around the joint. Only after the joint swelling has decreased, can mobilisation splinting be effective.

As healing proceeds, the injured healing capsular structures thicken and independent tissue layers adhere, providing resistance to full motion. The PIP joint often is bulbous from this tissue thickening and the bulbous shape makes the fitting of a mobilisation splint difficult.

These many factors combine to make resolution of a PIP joint limitation a challenging task. Mobilisation splints are the most frequently used method of regaining PIP joint motion following isolated PIP injury. Not all PIP mobilisation splints are equally effective. The purpose of this article is to review the mechanics of a variety of PIP mobilisation designs the author has found effective.

To efficiently apply mobilisation splints to the resistive PIP joint, the hand therapist needs an understanding of wound healing and biomechanics that exceeds the scope of this paper. Therapists are encouraged to review the rationale of mobilisation splinting in other texts (Brand 1990, Brand and Hollister 1993, Colditz 1983, Colditz 1995c and McKee and Morgan 1998).

BIOMECHANICS OF PIP EXTENSION

MOBILISATION SPLINTING

An effective PIP mobilisation splint must:

- Localise the mobilisation force to the PIP joint while eliminating force to the more mobile MP and DIP joints.
 - Apply three efficient points of pressure to mobilise the PIP joint into extension or flexion.
- Every splint applied to either immobilise or mobilise a joint must precisely apply three points of pressure. The middle force is directly over the axis of the joint (in this case the PIP joint) and the two opposing forces are as far away from the middle force as possible without crossing another joint (Figure 1a and b).

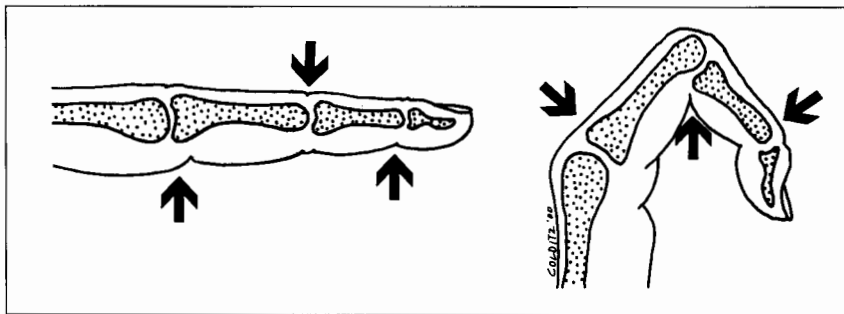


Figure 1a and b

PIP mobilisation splints must have three directions of forces for a. extension and b. flexion.

PIP extension mobilisation splinting requires the middle force be applied dorsally directly over the PIP joint. With little padding over the bony condyles, pressure is poorly tolerated here. This counter-pressure point may be moved just proximal to the joint and remain effective, but the distal edge of the counterpoint should rest exactly at the axis of the PIP joint if the forces are to be maximally effective.

When PIP extension mobilisation splints apply force at the distal palmar point, the DIP joint will hyper-extend if the force is applied beyond the DIP joint. The short length of the middle phalanx, especially on the little finger, minimises the effectiveness of this distal lever arm. Splints that immobilise the DIP joint while applying an extension mobilising force to the PIP joint will increase the effectiveness of the distal lever arm.

Many PIP extension mobilisation splints end proximally at the finger web spaces. This length is only slightly more than one-half the span of the proximal phalanx. PIP extension mobilisation splints have greater mechanical advantage to extend the PIP joint if the proximal end of the splint is extended the full length of the proximal phalanx.

The PIP extension mobilisation splints discussed below incorporate these basic mechanical principles into their design and have been found by the author to provide effective PIP mobilisation solutions to a variety of PIP joint problems.

PIP EXTENSION MOBILISATION SPLINTING: CLINICAL PROBLEMS AND SOLUTIONS

Clinical Problem 1: PIP Extension Lag

Minor injuries to the PIP joint will frequently cause joint distension and capsular thickening. There will be resistance to the last few degrees of PIP extension and an extension lag results. In such circumstances the use of a PIP extension immobilisation splint at night in the position of full PIP extension will usually resolve the problem while also reducing the joint size.

- Available from Smith and Nephew
- Available from WFR Corporation
- Available from North Coast Medical, Inc.

The challenge in constructing a small splint that effectively holds the PIP joint fully extended is the task of holding the warm thermoplastic splinting material around the finger while also maintaining the PIP joint in a position of full extension. This is solved by using a 1/16-inch thick coated thermoplastic material with memory that also become translucent when heated: Aquaplast®•, Reveal®•• or Encore™••• (1/12" Prism™ may also be used [white only].•••) The translucent material allows the dorsal seam to be safely trimmed close to the skin. The coating permits the warm material to temporarily adhere but then easily snap apart when cool. The memory encourages the material to hug the digit after the material is stretched around it.

Splint Construction Tips

Cut a shape wider than the circumference of the finger and slightly longer than the length of the finger with a flange in the middle of the proximal aspect (Figure 2). Wrap the warm splinting materi-

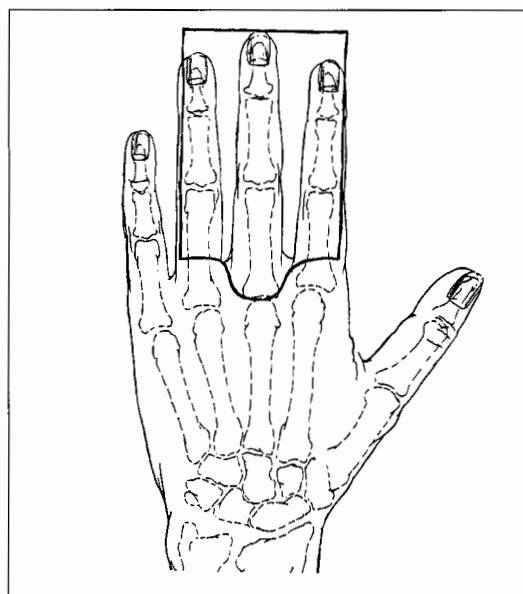


Figure 2

Pattern for PIP extension mobilisation (or immobilisation) splint made of 1/16" splinting material

al completely around the finger with the material placed as far proximally on the finger as possible. Pinch the material together on the mid-dorsum of the finger and immediately cut off the extra material longitudinally to create a flat dorsal seam. This seam holds the tube shape together while the therapist fully extends the PIP joint until the material cools. Pressure may be applied directly over the PIP joint to hold the PIP joint extended, as the dorsal material will be eliminated. Counter-pressure is concurrently applied proximally over the flange at the palmar base of the proximal phalanx and under the DIP joint. Before removal of the splint, mark the mid-lateral point of the splint on

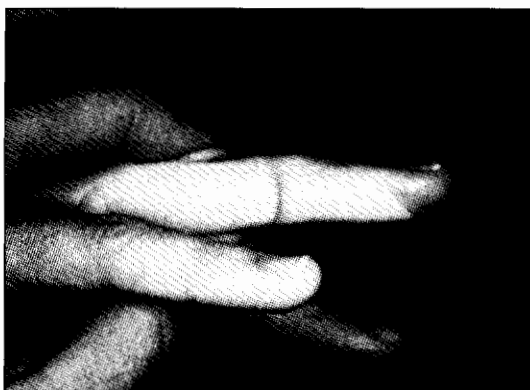

Figure 3a
A PIP extension splint should hold the PIP fully extended and be moulded with enough counter-curve so the splint is a strong shape.

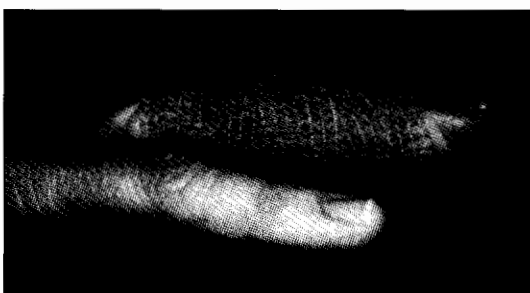


Figure 3b
Selfadherent wrap is a useful means to maintain the digit in full extension while also providing compression to reduce oedema around the joint.

the radial and ulnar aspect of the digit. When the material is cool, snap it apart at the dorsal seam and cut it off at the mid-lateral lines drawn (Figure 3a).

In cases where the joint is fluctuant, the author prefers to use Coban®, a self-adherent elastic bandage material, rather than hook and loop fastener to secure the splint (Figure 3b). The Coban® worn at night maintains the extended position while also reducing oedema.

Night use of the splint will resolve a minor extension lag that results from increased resistance within the joint. If the joint is resistive to passive extension and the joint is not fluctuant, then a static progressive extension splint may be the splint of choice.

Acute boutonniere injuries may be managed by using the palmar digital splint with Coban® (Figure 3b) until full PIP extension is gained and the joint size reduced. After the initial joint oedema has subsided, the identical splint design is refitted to conform to the smaller finger size. After trimming the splint on the radial and ulnar borders, the end is cut off at the DIP flexion crease. This edge is warmed and rolled, allowing comfortable DIP flexion. A dorsal piece of splinting material is then moulded directly over the PIP joint. The dorsal piece overlaps the palmar piece slightly on each side and holds the PIP joint fully extended while distributing pressure over the dorsal surface. The overlap design creates a full circle of thermoplastic

material and this rigid shape holds the PIP joint securely. The splint must be remoulded as the size of the PIP joint continues to diminish. It is not mandatory to leave the DIP joint free until the PIP joint oedema has resolved and the joint can be securely held in full extension.

Rather than using a hook and loop strap to hold the halves together, the author prefers adhesive tape for those patients who are wearing the splint full time to protect the healing boutonniere injury. The adhesive tape prevents the two pieces moving in relation to one another and decreases the bulk of the splint.

CLINICAL PROBLEM 2: PIP FLEXION

CONTRACTURE RESPONSIVE TO STRETCH

PIP joint injuries seen a few weeks following injury may exhibit limited active and passive PIP joint extension. Clinical examination will reveal the joint is responsive to the passive extension force. Such joints respond readily to intermittent wear of a dynamic PIP extension mobilisation splint (Figures 4a and b). A custom fitted spring wire splint either with or without a coil is the author's choice (Callahan and McEntee 1986, Colditz 1995b).

Although numerous commercial splints of similar design are available, having a commercial splint available that fits the patient as accurately as a custom splint is rare. The reader is encouraged to review previous publications for the specifics of construction of the spring wire splint (Callahan and McEntee 1986, Colditz 1995b, Wynn Parry, 1978).

Splint Construction Tips

The advantage of the custom splint is the ability to accommodate the bulbous PIP joint and distribute pressure precisely and comfortably. The axis of the coil is exactly at the PIP joint axis. The extension force is adjustable via the hook and loop closure.

Making the distal lever arm longer increases its efficiency. The potential of DIP joint hyperextension is eliminated by moulding a DIP extension immobilisation splint that is worn as part of the PIP extension mobilisation splint (Figure 4a).


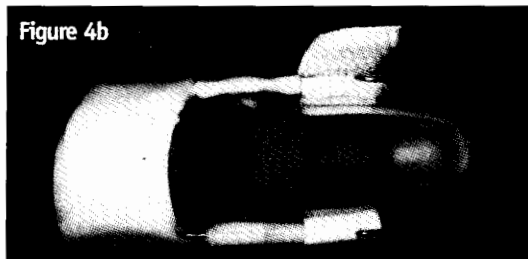


Figure 4a
Dynamic PIP extension mobilisation splint is made of spring-steel piano wire, without coils. The distal interphalangeal joint (DIP) is immobilised with a palmar splint to increase the effective length of the distal lever arm, and prevent DIP hyperextension.



CLINICAL PROBLEM 3: PIP JOINT CONTRACTURE UNRESPONSIVE TO STRETCH

Longer standing PIP flexion contractures or those contractures of more than 30-45 degrees cannot effectively be treated with dynamic PIP extension mobilisation splints. These more resistive contractures require serial static extension mobilisation splinting using plaster of Paris casting. This technique is well documented in the literature (Bell 1987, Bell-Krotoski 1995) and the reader is encouraged to review the technique as described.

The author has found that the problems of potential DIP hyperextension and the need to extend the proximal edge of the cast the length of the proximal phalanx can be resolved by altering the cast application technique (Colditz & Schneider 1995a). The use of Gypsona (plaster of Paris), a creamier plaster with a fine gauze, will facilitate a smooth and well-fitting digital cast.

MODIFIED CAST CONSTRUCTION TECHNIQUE

A thin cast is first applied to encircle the DIP joint and this is allowed to slightly harden. (Figure 5a) A piece of plaster of Paris is then applied palmarly, extending the length of the proximal phalanx (from the palmar PIP joint crease to the distal palmar crease) (Figure 5b). After the palmar piece has hardened slightly, a small strip of plaster is applied the length of the palmar piece and moulded to create a triangular shape. This reinforces the proximal flange, which would otherwise readily break. One-inch wide plaster of Paris is then applied to encircle the digit and the previously applied plaster pieces. The author has altered the technique as originally published in 1995, as the use of a thermoplastic material to reinforce the proximal flange sometimes creates maceration. The plaster of Paris shaped into a triangle is used instead.

The advantage of this modified technique is the ability to elongate the proximal and distal lever arms of the cast. When gently passively extending the PIP joint as the plaster of Paris hardens, with the modified technique one need not fear applying excessive pressure over the dorsum of the PIP joint (Figure 5c). Force can safely be applied proximally and distally to extend the joint as these areas have hardened plaster underneath.

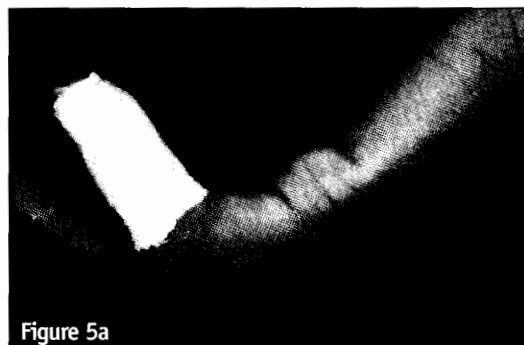


Figure 5a

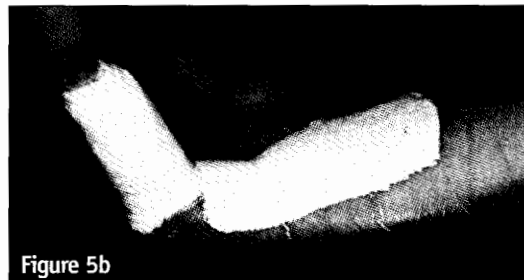

Figure 5b

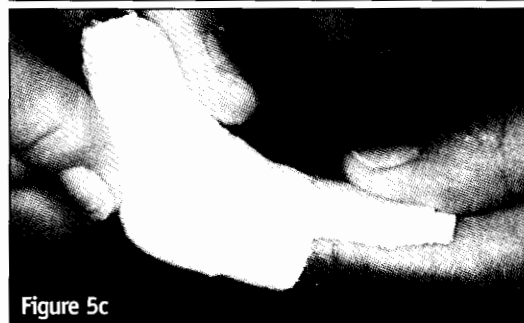

Figure 5c

Figure 5a, 5b, 5c

A modification of the digital serial plaster casting technique for PIP extension mobilisation uses a. a small cast to immobilise the DIP joint and b. a palmar plaster slab to increase the proximal lever arm length. With a and b allowed to harden, plaster of Paris is then applied and c. extension forces can be applied without fear of undue pressure to underlying tissues.

CLINICAL PROBLEM 4: GAINING OR MAINTAINING THE LAST FEW DEGREES OF PIP EXTENSION IN A RESISTIVE CONTRACTURE

Following either dynamic PIP extension mobilisation splinting or serial static PIP extension mobilisation splinting, frequently the patient has difficulty maintaining the last few degrees of PIP extension. Often at this stage the intermittent wear of the dynamic splint is less effective and continuation of serial casting is impractical. In this circumstance the author has found a custom moulded static progressive PIP extension mobilisation splint most effective (Figures 6a-c and 7). Any 1/8-inch thick thermoplastic material maybe used except those highly resistive to moulding. The palmar portion of the splint is moulded in a position of full PIP extension, not on the patient's finger. The splinting material under the DIP joint is angled towards flexion. This prevents the PIP extension force from hyper-extending the DIP, a subtle but important part of the success of this splint

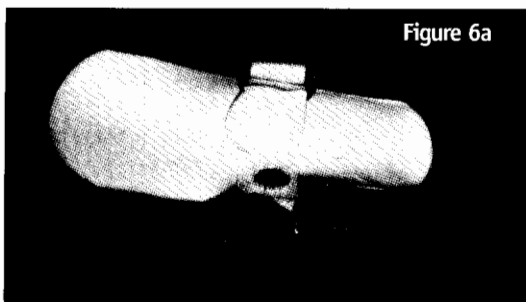


Figure 6a




Figure 6b

Figure 6a & 6b

A serial static PIP extension mobilisation splint is moulded to position the joint in full extension but avoid hyperextension of the DIP joint.

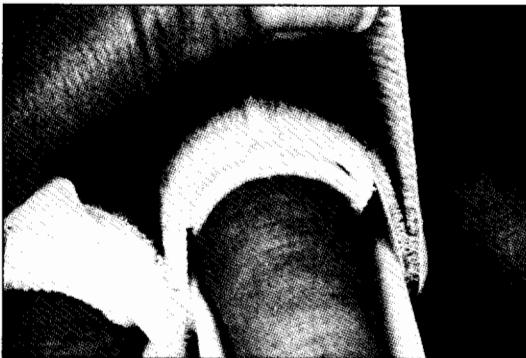

Figure 6c

A custom moulded piece over the dorsum of the proximal phalanx allows comfortable distribution of the middle point of pressure.

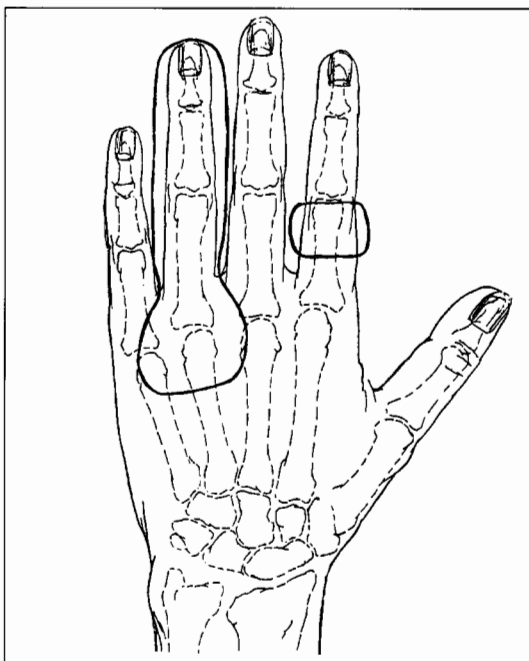


Figure 7

Pattern for the dorsal and palmar thermoplastic pieces for the PIP flexion mobilisation splint is illustrated on different fingers for image clarity.

design. The custom moulded dorsal piece distributes pressure comfortably as the PIP joint is fully extended (Figure 6c). A narrow (1/2-inch) hook and loop strap with a 1/2 inch D-ring[•] allows the patient to precisely tighten the splint and apply progressive pressure to the dorsal piece.

This design is only effective for gaining the last few degrees of PIP extension.

FLEXION MOBILISATION SPLINTING: CLINICAL PROBLEMS AND SOLUTIONS

As with PIP extension, there are many reasons for the patient's inability to gain full PIP flexion. This article does not allow adequate discussion of all clinical circumstances limiting PIP flexion, i.e. capsular adherence, tightness of the intrinsic muscles, adherence of the extensor mechanism/extrinsic extensors, or inadequate/adherent flexor system. The splint discussed below is useful for PIP flexion mobilisation when the limitation is the result of an isolated to the PIP joint problem, when the concurrent position of proximal joints is irrelevant.

The three points of pressure needed for effective PIP flexion mobilisation splinting are reverse from extension splinting. The three points are 1) palmarly under the PIP joint 2) dorsally over the distal end of the middle phalanx and 3) dorsally over the proximal end of the proximal phalanx (Figure 1b). The difficulty in application of these points of force is the impossibility of applying force directly over the palmar aspect of the PIP joint while still allowing room for the joint to maximally flex. Application of the dorsal pressure over the dorsum of the MP joint may be uncomfortable due to the bony contour with little natural soft tissue padding.

Unlike PIP extension mobilisation splinting where the forces are almost in direct opposition, PIP flexion mobilisation splinting forces may be almost at right angles to one another (Figure 8a and b). With right angle forces the splint base shifts distally as the force is applied if the resistance to PIP flexion is greater than the stability of the splint on the hand. PIP flexion mobilisation splint designs frequently block full PIP flexion rather than facilitating it. The author has used a splint design for many years that effectively eliminates these mechanical problems (Colditz 1983, Colditz 1996).

Van Veldhoven has suggested a PIP swing traction splint that mobilises the PIP joint through a full range of flexion (Van Veldhoven 1995). This design minimises the right angle forces, reducing the likelihood of distal migration. The Van Veldhoven design calls for a dorsal strap over the

• Available from North Coast Medical, Inc.

MP joint to maintain it in extension. In cases of a resistive PIP joint, the author has found that the MP joint needs more rigid support in extension than a dorsal strap provides.

CLINICAL PROBLEM 5: LACK OF PIP FLEXION

With an isolated PIP joint problem it is acceptable to position the normal MP joint in full extension while mobilising the PIP joint into flexion. By doing this, room is created to apply an outrigger that provides a 90-degree angle pull to the distal end of the middle phalanx. As the PIP joint gains flexion, the length of the outrigger is shortened to maintain the line of pull. Additionally, if PIP joint flexion is extremely limited, the palmar block over the proximal phalanx needs to be longer to stabilise the proximal phalanx. When the splint is to gain the last few degrees of PIP flexion the block must be much shorter so as not to impede full PIP flexion (Figure 8a and b).

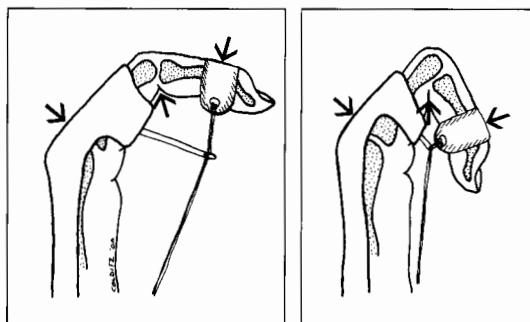


Figure 8a
In the beginning ranges of PIP flexion, the PIP flexion mobilisation splint must have a longer proximal phalanx block and a longer outrigger than b.

Figure 8b
PIP flexion mobilisation splint in the end ranges when the proximal phalanx block and the outrigger need to be shorter.

The splint base is designed to immobilise the MP joint in extension while obliquely crossing the dorsum of the metacarpals and wrapping around either the radial or ulnar aspect of the metacarpal bases (Figure 9a and b). The splint is held in place by a strap placed at a 45-degree angle on the opposite side around the base of the metacarpals. This moulding and strapping takes advantage of the enlarging circumference of the hand just distal to the wrist and prevents the splint from slipping distally when force is applied to flex the PIP joint. When the ring or little finger PIP joint is injured the splinting material is wrapped around the radial aspect of the wrist. When the index or long fingers are involved the material is moulded around the ulnar aspect. Before applying a flexion force to the PIP joint, the splint must be moulded intimately and the strap applied securely to assure no distal migration is possible.

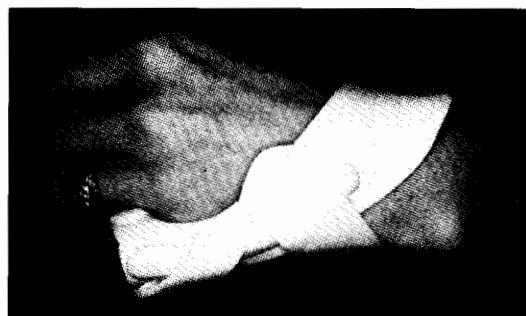


Figure 9a
Dorsal view of the PIP flexion mobilisation splint design shows the obliquity of the design that assists in minimising distal migration.

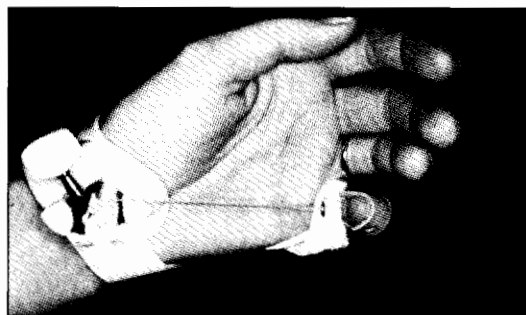


Figure 9b
Volar view shows the use of a banjo tuner to apply a serial force.

SPLINT CONSTRUCTION TIPS

The design of this splint necessitates that a narrow and relatively flat piece of splinting material is moulded dorsally across the extended MP joint (Figure 10). This flat shape is a weak point and the splint will bend here rather than mobilise the resistive PIP joint if this piece is not strengthened. Bonding another piece of splinting material moulded into a triangular shape longitudinally across the dorsum of the MP joint will adequately reinforce this area. The triangular shape is stronger than a flat piece of splinting material.

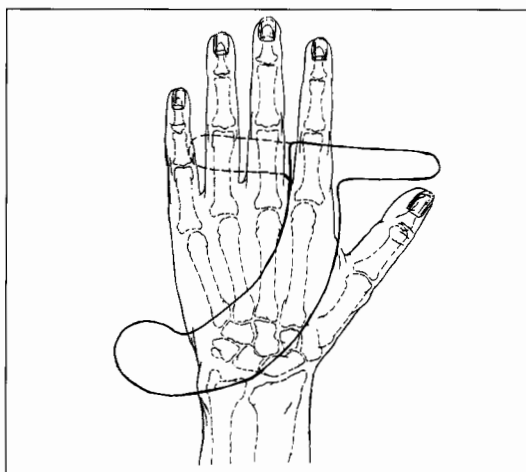


Figure 10
Pattern for the PIP flexion mobilisation splint shows that the distal flange may be cut either direction. The obliquity of the pattern depends on the finger involved: the base of the splint for the index and long fingers wraps around the ulnar border and for the ring and little fingers wraps around the radial aspect.

The part of the splint that encircles the finger must be carefully moulded so the splint can be removed over the bulbous PIP joint, but can also be tightened to adequately stabilise the proximal phalanx. Either a dynamic or static progressive flexion force may be used with this design. The author's experience is that dynamic force is more comfortable at the end range of PIP flexion. Static progressive forces appear more effective and comfortable for the end ranges of PIP extension than flexion.

CONCLUSION

This article has presented PIP flexion and extension mobilisation splint designs the author has found effective. Following a general discussion of mobilisation mechanics, examples of isolated PIP joint problems have been discussed. Both extension and flexion mobilisation splints have been discussed relevant to isolated PIP joint problems with suggestions for specific designs and tips for successful construction.

ADDRESS FOR CORRESPONDENCE:

Judy C. Colditz OTR/L CHT FAOTA
 Consultant in Hand Therapy
 RHRC/HandLab Inc
 2615 London Drive
 Raleigh NC 27608
 USA
 Tel: 919-781-3189
 Fax: 919-782-2269
 E-mail: JCColditz@aol.com

REFERENCES:

- Bell-Krotoski JA (1995):** Plaster cylinder casting for contractures of the interphalangeal joints. In: Hunter JM, Mackin EJ and Callahan A (Eds.) *Rehabilitation of the Hand*, 4th ed. pp 1609-1616. *St Louis: Mosby*.
- Bell JA (1987):** Plaster casting in the remodeling of soft tissue. In: Fess EE and Philips CA (Eds.) *Hand Splinting: Principles and Methods*, 2nd ed. pp. 449-466. *St. Louis: CV Mosby*.
- Brand PW (1990):** The forces of dynamic splinting; ten questions before applying a dynamic splint to the hand. In: Hunter JM, Schneider LH, Mackin EJ and Callahan A. (Eds.) *Rehabilitation of the Hand*, 3rd ed. *St. Louis: CV Mosby*.
- Brand PW and Hollister A (1993):** *Clinical Mechanics of the Hand*, 2nd ed. *St. Louis: Mosby Year Book*.
- Callahan A and McEntee P (1986):** Splinting proximal interphalangeal joint contractures: a new design. *Journal of Hand Therapy* 40: 408-413.
- Colditz JC (1983):** Low Profile Dynamic Splinting. *American Journal of Occupational Therapy* 37: 182-188.
- Colditz JC and Schneider AM (1995a):** Modification of the digital serial plaster casting technique. *Journal of Hand Therapy* 8: 215-216.
- Colditz JC (1995b):** Spring-Wire Extension Splinting of the Proximal Interphalangeal Joint. In: Hunter JM, Mackin EJ and Callahan AD (Eds.) *Rehabilitation of the Hand*, 4th ed. pp. 1617-1632. *St. Louis: Mosby*.
- Colditz JC (1995c):** Therapist's Management of the Stiff Hand. In: Hunter JM, Mackin EJ and Callahan AD (Eds.) *Rehabilitation of the Hand*, 4th ed. pp. 1141-1160. *St. Louis: Mosby*.
- Colditz JC (1996):** Principles of Splints and Splint Prescription. In Peimer C (Ed.) *Surgery of the Hand and Upper Extremity*, pp. 2389-2410. *New York: McGraw-Hill*.
- McKee P and Morgan L (1998):** *Orthotics in Rehabilitation*, Philadelphia: FA Davis Company.
- Van Veldhoven G (1995):** The proximal interphalangeal joint swing traction splint. *Journal of Hand Therapy* 8: 265-268.
- Wynn Parry CB (1978):** *Rehabilitation of the Hand*, 3ed. *Sevenoaks, UK: Butterworths*.