

OBSTETRICAL BRACHIAL Palsy

*The hand therapist's role**

Judy C. Colditz

Obstetrical brachial palsy (OBP) results from stretching of the brachial plexus as the baby passes through the birth canal. If the baby's head and shoulders are pulled in opposite directions during delivery, the upper part of the brachial plexus is stretched (Erb's palsy). Breech deliveries can cause injury to the lower part of the plexus (Klumpke's palsy) when the arms of the child are hyperextended overhead. This lower cord stretch also commonly occurs when there is a face presentation and the neck is hyperextended.³

The reported incidence of OBP varies from 0.04 to 2.5 per 1000 live births.^{11,15,22,26} This condition is associated with large-birth-weight infants and difficult deliveries.^{3,22} Fortunately, sophisticated obstetrical management is decreasing the incidence of this birth-related injury.¹⁸

HISTORY

Smellie, in 1768, was the first to write a clinical description of this problem.²⁵ He documented the observation of resolution of bilateral upper extremity paralysis in a child with face presentation at birth. Danyau performed an autopsy of a newborn with brachial plexus palsy in 1851, providing the first anatomic description of this lesion.⁴

In 1872 Duchenne described traction to the arm in infants and identified the lesion as being the upper part of the brachial plexus.⁵ Two years later Erb described electrical stimulation of this lesion in children and adults.⁷ Although

Duchenne first described the lesion, Erb's name is commonly associated with it²²; *Erb-Duchenne palsy* is an equally correct term for this lesion.¹⁶

The less common lower brachial plexus injury was described by Klumpke in 1885.¹⁷ This lesion is an injury to the roots of C8 and T1.

DIAGNOSIS

The newborn presentation is often suggestive of absent muscle function. Absence of normal arm motor response to the startle, grasp, and Moro reflexes are observed, and deep tendon reflexes are absent.³ A clear diagnosis of the specific muscles involved is at best difficult, because newborns cannot respond to muscle testing commands.

To further complicate an accurate diagnosis, these lesions are often partial or combinations of the classic descriptions. Frequent clinical examinations are required before muscle function can be fully and accurately observed. X-ray films must substantiate the absence of bony injury to the proximal humerus or clavicle before the diagnosis of brachial plexus injury can be confirmed.^{1,14,24}

Electromyographic (EMG) examination, although technically difficult in the young child, is the most objective means of evaluation. Eng and associates state that EMGs can predict the final reinnervation outcome after the second or third examination.⁶ Other authors feel that EMGs are most helpful in predicting the surgical findings and for planning operative procedures.²⁷ Some feel that serial clinical examination is all that is needed to determine the prognosis.¹⁵

*This chapter is dedicated to the memory of John Wesley Packer, M.D., 1939-1993.



Fig. 25-1. The absence of shoulder motion prevents the child from crawling. The child may demonstrate the ability to support the weight of the upper body on the elbow.

PROGNOSIS

There is disagreement about recovery rates from obstetrical palsy.^{3,10,14,15} Accuracy is clouded by the fact that many infants seen only by obstetricians spontaneously recover in the first few days or months. Those writing about long-term results are surgeons who rarely see children with early spontaneous resolution.

Determination of muscle return may be difficult to determine because the normal development of the child progresses simultaneously. The unskilled examiner may have difficulty identifying what is return and what is the appearance of normal developmental movement. Functional impairment of the upper extremity is obvious when the child is ready to crawl, as the arm simply does not work properly (Fig. 25-1). As the child begins to walk independently and begins two-handed activities, the examiner may assume there is significant progress. Although it is encouraging to the parents and examiner that the child is using the hand functionally, this use as an assist in bilateral activities may not necessarily indicate progressive muscle return³ (Fig. 25-2).

In the earlier part of this century, because of the discouraging surgical results, most surgeons were pessimistic about operating on OBP.¹³ Results from large surgical series reviewed more recently have shown improved functional results when the patients are selected for surgery according to precise criteria.⁸

Hoffer reports that all children he saw with only shoulder problems recovered completely.¹⁵ The prognosis is worse for children with lower plexus and complete lesions.¹⁵ The

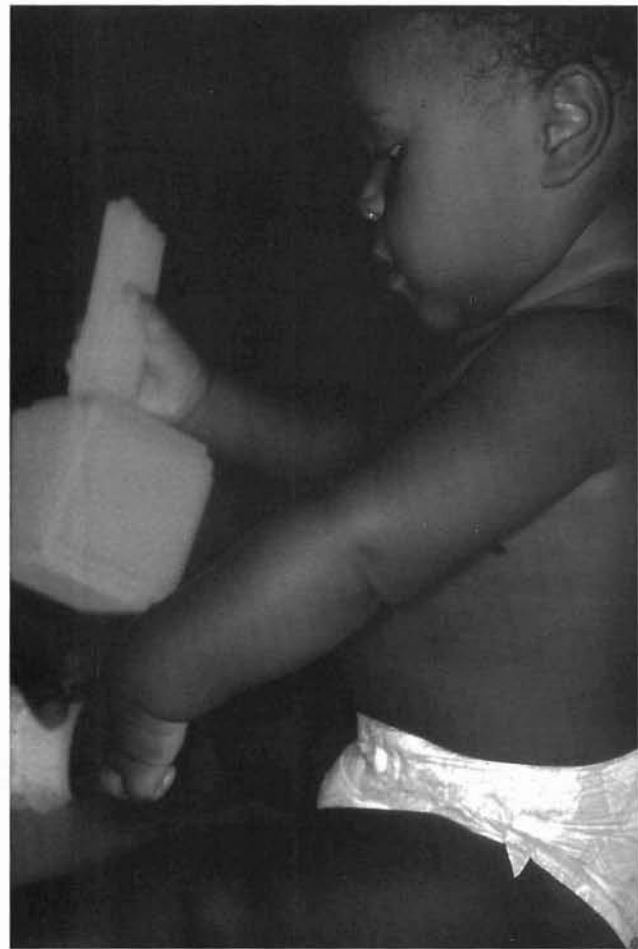


Fig. 25-2. The involved arm is used in bilateral activities that are within range of the limited shoulder flexion.

presence of Horner's syndrome carries a very poor prognosis in the children with complete lesions.^{13,14} As with any nerve regeneration, the earlier and more extensive the return observed, the better the prognosis. In OBP most of the progress is seen in the first year of life and can be expected to reach maximum return by 24 months. Unlike adults, however, some children can demonstrate continued return of function up to 4 years following birth.¹⁵

Most authors agree that if biceps function is not seen by 3 months, then the prognosis for functional return is poor.^{2,13,14,22,27} Many recommend surgery if the biceps is not active by this time.^{2,13,22} Surgery can be expected to provide one grade higher of muscle function than if the child is treated conservatively.²²

COMMON PLEXUS LESIONS

Upper plexus lesion: Erb-Duchenne palsy

Erb-Duchenne palsy is by far the most common involvement seen and has the most encouraging prognosis.¹ Many of these children undergo full spontaneous recovery within the first 3 months.⁹ Classically this lesion has been described as involving the roots of C5-C6, but Terzis, Liberson, and

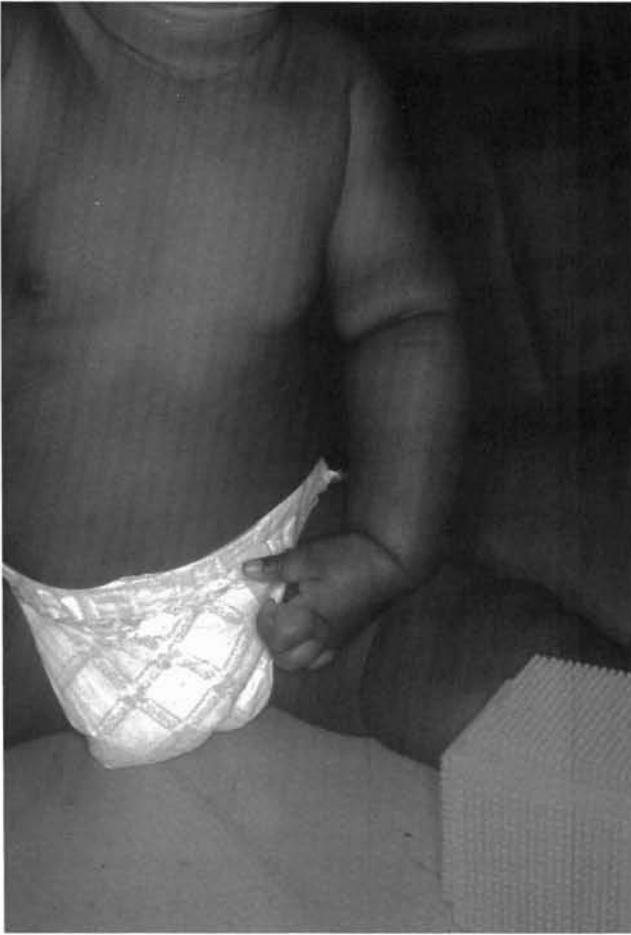

Fig. 25-3. The typical presentation of Erb-Duchenne palsy is demonstrated by the arm at the side with elbow extended and the shoulder internally rotated. The forearm is pronated and the fingers and wrist flexed.

Levine conclude that the C7 root is almost always involved.²⁷

Children with Erb-Duchenne palsy present with the involved arm limp at their side, the shoulder internally rotated, the elbow positioned in full extension, the forearm pronated, and the fingers and wrist flexed³ (Fig. 25-3). The shoulder is adducted because of the paralysis of the deltoid and supraspinatus muscles. The active pectoral and subscapularis muscles and inactive infraspinatus and teres minor keep the shoulder internally rotated.³ Elbow extension is usually produced by gravity and paralysis of the elbow flexors: biceps, brachialis, brachioradialis. The absence of the biceps and supinator contribute to the pronated position.³ The involvement of C7 means that the extrinsic wrist and finger extensors are absent.²⁷ These children have unopposed finger and wrist flexion and thus will progress to demonstrate extrinsic finger flexor tightness. Distal sensibility and vasomotor control are usually unaffected.⁹

Residual weakness is commonly seen in these patients. It is a pattern of weakness sometimes coupled with lack of a

full range of motion in shoulder abduction, flexion, and external rotation, as well as elbow flexion and forearm supination. The child has the frustrating situation of being unable to position the normal hand so it can be used. In addition, the child may have weakness or absence of wrist and finger extension.¹⁵

Low plexus lesion: Klumpke's palsy

Klumpke's palsy or injury to C8-T1 roots also frequently includes injury to the C7 root.²⁷ This injury carries a poor prognosis and is rarely seen in pure form. Gilbert and Whitaker quote Wickstrom as noting that less than 10% of patients with Klumpke's palsy will recover any useful function, and thus surgical intervention should be considered at 3 months.⁹

A Klumpke's lower plexus palsy leaves the child with good proximal control but absence of intrinsic and extrinsic hand muscles. The absence of C7 function prevents return of the long extensor muscles of the hand and wrist.²⁷ Residual weakness of the hand always remains, usually with accompanying critical loss of sensibility in the hand.

Complete plexus lesion

Damage to the entire plexus, although rare, does occur. There is complete sensory and motor paralysis of the extremity, and the hand is clawed. The presence of Horner's syndrome is an indicator of severe involvement, worsening an already poor prognosis. Distal sensory impairment causes a vasomotor disturbance, and the hand presents with a pale marbled appearance.⁹

CLINICAL EXAMINATION OF A CHILD WITH OBSTETRICAL BRACHIAL PALSYP

Platt, Hudson, and Hoffman state that examination of an infant with OBP is "a matter of seduction; gentleness, patience, and trickery . . ." ²³ The skill of the examiner is put to the ultimate test with an infant who cannot respond to requests or commands. Infants may not spontaneously exhibit certain movements when they are developmentally unable to do so.

Muscle testing

Muscle testing in the newborn is at best inaccurate because the examiner can rely only on reflex testing and observation of spontaneous movement. Direct palpation of muscles can pick up early activity, although the ability to elicit this activity is variable. EMG testing plays an early role in defining muscle activity and is helpful in determining early surgical treatment options. Keen observation during numerous visits over time is the best means to determine reliably the functional level of muscle activity. Videotaping provides objective documentation of motion on serial visits.

Many authors suggest using a simplification of the British Medical Research Council muscle testing classification

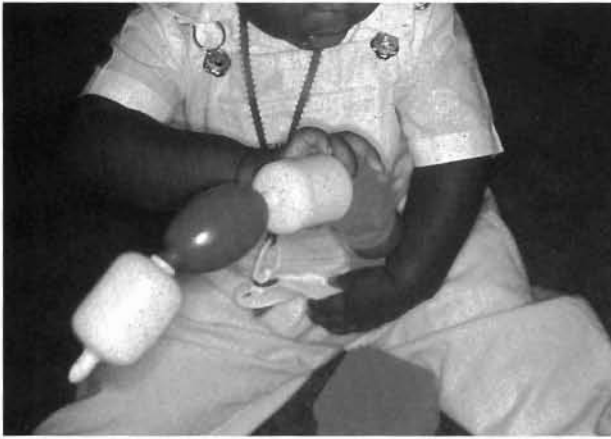

Fig. 25-4. Toys requiring bilateral skills are one of the best means to assess functional use of the extremity at an early age.

because it more easily accommodates the difficulty of muscle testing in a small child.

M0 = no contraction

M1 = contraction without movement

M2 = slight or complete movement with weight eliminated

M3 = complete movement against the weight of gravity^{8,10,12-14}

Sensibility evaluation

Sensory testing in the newborn is an even greater challenge than observation of muscle activity. Intact sensory status can only be assumed as the baby withdraws from painful stimuli. In older children a reaching response to stimuli or searching for the stimulus visually assures the examiner of some level of intact sensibility. Over time, trophic changes such as nail and hair growth and changes in finger color provide additional evidence. Normal neurophysiologic development will increase the child's grasp and reaching response to stimuli. As with manual muscle testing, the therapist must be knowledgeable about the normal stages of grasp and prehension development to accurately evaluate the disability of the extremity.

THERAPIST'S ROLE IN REHABILITATION

Technology cannot replace the fundamental role of the therapist as critical observer. The therapist uses age-appropriate play activities to assess the functional and developmental disability resulting from the motor loss. An environment providing stimuli appropriate to the child's developmental level is the best means of accurate evaluation (Fig. 25-4). Observation in this group of patients is often a more critical skill than manual examination.

Even when sensory and motor return does occur, the child often ignores the arm³ (Fig. 25-5). The key to therapy is helping the child develop an awareness of the arm and its useful potential. The focus of therapy should therefore

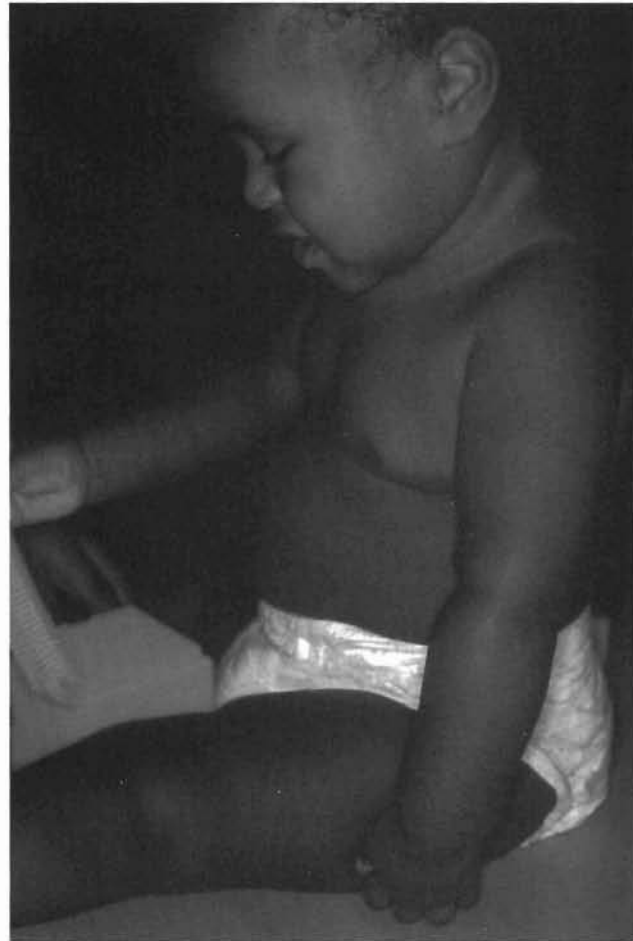


Fig. 25-5. A child with some motor function often ignores the arm if the task requires only one hand.

consist of instructions to the parents about ways they can facilitate the use of the arm while motor and sensory function returns.

The therapist's role in the treatment of a child with an OBP lesion is also vital to the parents. Parents need reassurance, answers to simple questions, practical suggestions, celebration of milestones of improvement, and frequent discussions about the expectations of functional return.

Surprisingly, I could find no reference to the role of the hand therapist in the management of OBP. In adults with brachial plexus injuries (whether treated surgically or nonsurgically), the goals are clear: prevent joint contractures, facilitate muscle return, and assist in functional use of the extremity. There is no reason why they should be different in the child. But the child's inability to communicate and participate means these goals are accomplished differently from those in the adult.

Parent education

Parents should be educated about the nature of the injury so they may better understand how to protect the healing

stretched nerves and the joints with weakened muscle support and control. Immediately following birth, the child's arm should be rested against the body for the first few weeks.²² The newborn should be handled by cradling under the head and pelvis and should not be picked up under the arms. The parents should be especially cautioned against pulling forward and upward on the arms to bring the child to a sitting position or to pick the child up. Instructing the parents to apply the child's garment sleeve to the involved arm first and remove it from the involved arm last will minimize the need to abduct or externally rotate the arm. Current precautions against placing children on their stomachs while sleeping (to reduce the risk of sudden infant death syndrome) require that the involved arm be held against the side of the body rather than be allowed to fall into external rotation while sleeping supine. Pinning the garment sleeve to the body portion of the garment will serve as a reminder to keep the child's arm against the body when sleeping, changing diapers, or handling the child.

Following the initial period of protection of the injured nerves (usually a few weeks), frequent passive range-of-motion exercises must be done by the parents to maintain normal joint motion. A routine of stretching exercises each time the diapers are changed is an excellent way to assure adequate frequency. Parents should be instructed specifically about each passive stretch position and then be able to demonstrate correct passive stretching techniques to the therapist. Full external rotation of the shoulder, for example, is difficult to maintain unless the parent understands the need to stabilize the scapula and ensure that motion is occurring at the glenohumeral joint. The most important passive stretches are full external rotation and abduction of the shoulder, full forearm supination and pronation, and concurrent wrist and finger extension (if the hand is involved).

When the child is old enough to roll over independently, the cautionary period of positional protection is long since past. Caution should remain against pulling the child up by the arm. If the child is able to crawl using the arm (some of these children skip the crawling stage), the parents should be cautious of the child bearing weight on the dorsum of a flexed wrist for prolonged periods.

Functional use of the arm is regained only as the child has both the motor ability to use the extremity and the awareness of the existence of the extremity. Without spontaneous motor ability, the hand and arm are deprived of frequent sensory input. Early rubbing and touching by the parents as well as passive motion for proprioceptive input are important. Even if the child cannot respond with motion, the arm should be stimulated each time the opposite uninvolved arm receives stimulation. Tickling of the arms simultaneously, holding the child's hands, playing patty cake, and placing the child's hand and arm on or around objects (Fig. 25-6) provide the consistent level of stimulation that can improve awareness as functional return occurs. Parents should not be allowed to

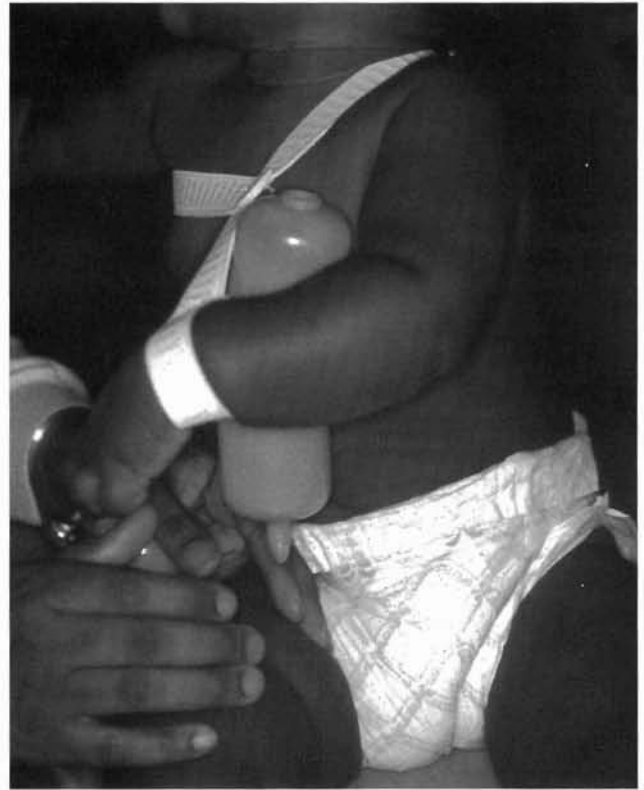

Fig. 25-6. Placing the child's arm around objects increases arm awareness. The elastic strap maintains elbow flexion.

believe that this stimulation will create return, but should understand it will enhance any naturally occurring return.

As the child reaches the developmental stage of actively bringing the arm to the midline, the parents should be instructed to bring the arm to the midline during passive play. The arm should be brought within the child's visual range. If the child with a weak shoulder can be placed in a special high chair with a high lap tray under the axilla and the food is placed so the child must reach for it, this becomes an active assistive exercise for shoulder motion. Parents should be encouraged to buy large toys such as balls that require both arms for holding (Fig. 25-7). As the child learns bilateral skills, interlocking toys, which require two hands to separate and join, should also be encouraged (see Fig. 25-4). Helping the parents with toy suggestions and play ideas to encourage reaching and manipulation maximizes the integration of sensory and motor return.

The therapist must know about developmental milestones. Therapy activities with these children can progress only as fast as their normally expected development. Therapists specializing in hand therapy may need to refer to developmental textbooks or consult with developmental colleagues to ensure accurate evaluation of functional status or to provide accurate suggestions for home therapy activities.




Fig. 25-7. Catching a large ball requires bilateral arm motion.

Most of all the therapist must reassure the parents. In circumstances where full return is unlikely, reassurance that the child can lead a relatively normal and healthy life despite the disability is crucial in the early years. Encouraging networking among parents of children with brachial plexus injuries, in my experience, is very positive.

Parents need to be reassured they are doing all they can to influence the progress of their child. Because they give the frequent daily stimulus, they are the primary therapy providers. Therapy sessions are only useful for documentation of progress, for solving problems, and for providing instructions to the parents about activities appropriate for the child until the next therapy visit.

Splinting

Splinting the hand can help gain and maintain passive motion of the hand; but splinting the elbow or shoulder is discouraged by some authors.^{19,22} This is because of complications reported by previous authors when prolonged periods of static splinting were used to hold the arm abducted and externally rotated.

As discussed previously, children with absent wrist and finger extensors have chronic tightness of the long flexor muscles. Splinting the hand with a resting splint that concurrently extends the wrist and fingers is appropriate (Fig. 25-8). If the child is seen within the first few months of life and demonstrates significant long finger flexor tightness, splinting on a full-time basis (with removal for skin hygiene) for a short period will greatly reduce the tightness. As the child grows, the splints should be limited to sleep time use only. During this period of development the goal is to encourage use of any prehension pattern possible




Fig. 25-8. A splint to maintain length of finger and wrist flexors requires multiple leather straps for adequate stabilization.

with the extremity. Use of a rigid hand splint during waking hours will only impede this goal.

Hand splints for children are difficult to make and to keep in place. Multiple conforming straps are necessary to keep the splint correctly positioned (Fig. 25-8). I recommend leather straps because they quickly conform to the shape of the extremity and minimize potential sharp edges or pressure areas. Because all young children have a large amount of subcutaneous fat and few defined bony prominences, prolonged pressure from the straps of a splint will deform the child's soft tissue so the strap impression may be evident long after the splint is removed. When the first hand splint is fitted, parents need reassurance that the ridging from the straps is a temporary phenomenon and not a long-term deformity.

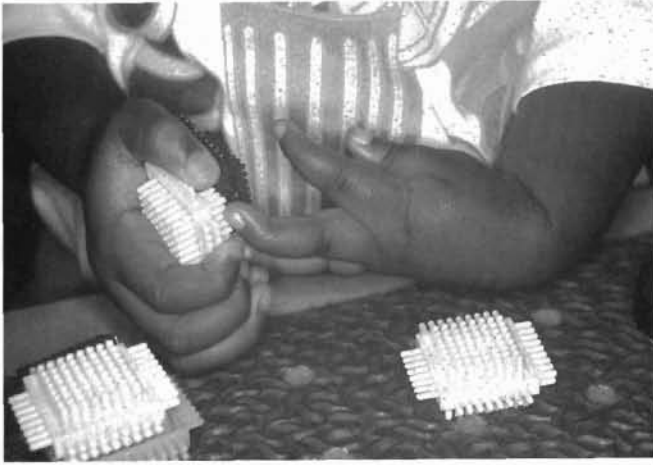

Fig. 25-9. The weak wrist extensors prevent stabilization of the wrist. The position of wrist flexion prevents opposition of the thumb to the fingers.

Children who chew or suck on the splint or remove it during sleep may require that Coban be wrapped over the splint for adequate protection. Parents must be cautioned about meticulous hygiene routines to prevent skin maceration.

In the child with active wrist and finger flexors but absent extensors, the pattern of usage is similar to the problem encountered in radial palsy. The active flexors cannot be used because of the inability of the patient to stabilize the wrist in extension while the force of the flexors is transmitted across the wrist (Fig. 25-9). These children often require long-term night splinting for the long flexor tightness and a day splint to stabilize the wrist so the child can hold objects in the hand. A small custom-made circumferential neoprene splint with a thermoplastic reinforcement may be all that is needed (Fig. 25-10). Children with stronger patterns of wrist flexion may need a molded thermoplastic splint for adequate stabilization (Fig. 25-11). The use of such a wrist splint allows for functional finger flexion, but the absence of intrinsic or extrinsic extensor muscles means that the child often cannot release objects placed in the hand. This factor is not enough, however, to suggest that the splint should not be used. The splint should be used intermittently based on the developmental age of the child and the task attempted.

Muscles undergoing nerve reinnervation should not remain stationary. It is appropriate to support a muscle so it can contract without having to first take up its fully stretched length. Simple splinting can assist muscle reinnervation. A simple elastic strap splint can be worn intermittently by the child to prevent a position of constant elbow extension (Fig. 25-12). The garment sleeve can also be pinned to the torso of the garment. This maximizes the ability to see early elbow flexion—a critical prognostic milestone for the child.

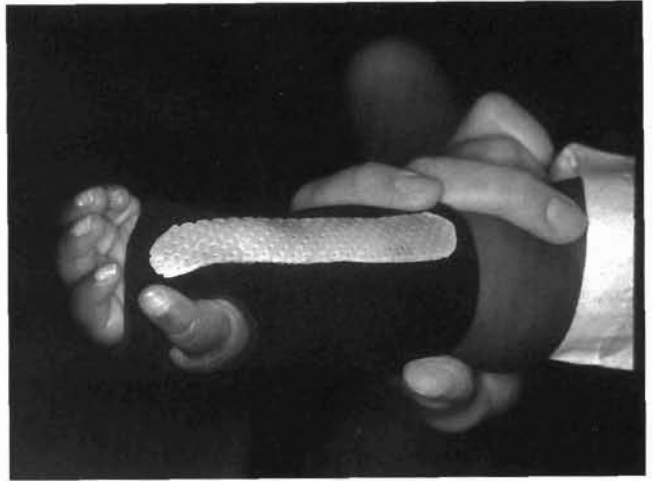

Fig. 25-10. A circumferential custom-made neoprene wrist splint with a thermoplastic stay provides wrist support but does not totally immobilize the wrist.



Fig. 25-11. Children who have developed strong wrist flexion need a molded thermoplastic splint to support the wrist and allow finger flexion.

Documentation of functional status

Comparison of surgical and nonsurgical results is hampered by the lack of definition of a standardized functional grading for a child's extremity.¹³ Mallet²¹ developed a functional classification of shoulder motion frequently referenced in the literature* (Fig. 25-13). This classification leaves much to be desired when describing hand function because it best evaluates children with upper plexus lesions where the shoulder is the site of the primary disability.⁸ It is limited to demonstration of shoulder function in older

*References 8, 10, 12, 13, 18, 19, 22.

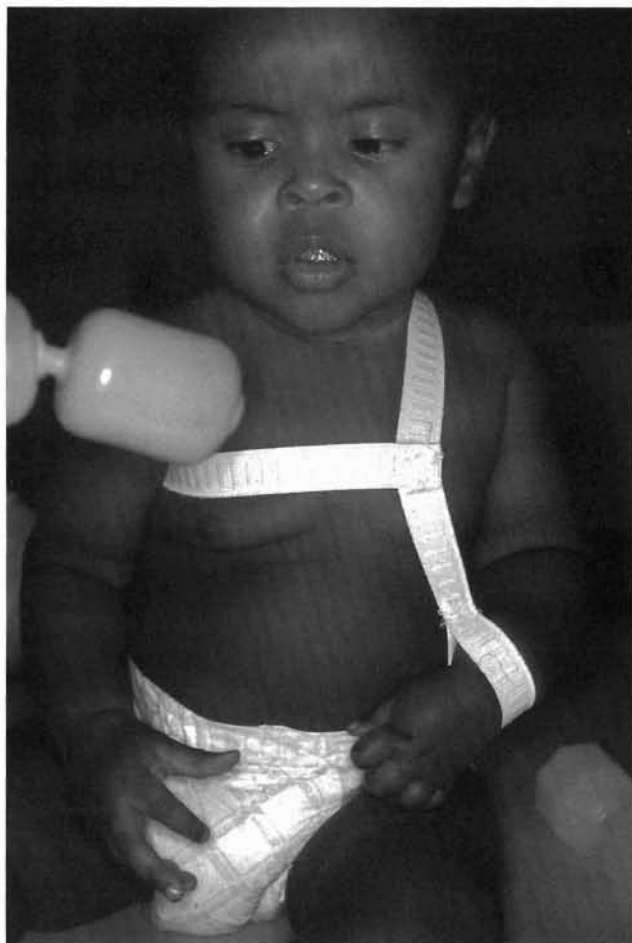


Fig. 25-12. An elastic strap supports the elbow in a flexed position.

children, as the child must be able to follow commands. Mallet's classification does not necessarily correspond with functional task ability. It is, however, a useful standard when surgeons attempt to compare surgical results and is most often used for that purpose.

Case study

B.W. is a cute, bright-eyed second child of normal gestation, who was first referred to hand therapy at the age of 10 months. Labor during her delivery was somewhat prolonged, but no specific complications were noted.

When she was first seen by an orthopedist at 3 weeks of age, no active arm motion was noted except perhaps finger flexion. At 4 months B.W. had some active shoulder flexion and elbow extension, but the critical milestone of elbow flexion was not present. Wrist and finger extension and all intrinsic hand muscles were also absent.

At 9 months wrist and finger flexion were clearly demonstrated as was the ability to stabilize the shoulder. There was still no elbow flexion or wrist and finger extension; both indicators of a poor prognosis.

At 10 months B.W. was referred to a hand surgeon who referred her to therapy. Although she had movement in her arm, she ignored her arm as if it were not part of her body (see Fig. 25-5). She held her elbow extended at all times but would initiate some shoulder flexion (see Fig. 25-2). Because she did not use her hand at all there was little reason to need the shoulder motion. She was not crawling. She would support her weight on the flexed elbow of her involved side for a short period (see Fig. 25-1) but would then roll to one side or roll over.

Her passive shoulder range was normal because of the mother's diligent stretching, but the range through which she used her shoulder was very limited (see Fig. 25-2). She used the arm to stabilize her body when sitting. The absence of wrist and finger extension prevented support on the palm of her hand. She would often bear weight on the dorsum of her flexed wrist. The functional use of the arm was limited to infrequent gross motor patterns of assist (see Fig. 25-2). She did not acknowledge objects placed in her hand but did acknowledge textured objects placed between her body and her proximal forearm area (see Fig. 25-6).

At the time of referral to therapy, tightness of the finger flexors was the only limited passive motion in the extremity (Fig. 25-14).

Initial treatment

The therapy goals were as follows:

1. To restore full passive motion (decrease long flexor tightness). This was accomplished by night and periodic day splinting to elongate the extrinsic flexors (see Fig. 25-8).
2. To protect the elbow from always being in a fully extended position to facilitate any return of elbow flexion. An elastic strap splint was fitted for periodic wear (see Figs. 25-6 and 25-12).
3. To increase self-awareness of her arm. The mother was instructed to position B.W. frequently sitting or prone with her arm positioned for support to provide a proprioceptive stimulus. The mother was asked to dress the child in short sleeves as much as possible and frequently place toys and objects between her body and the proximal forearm area. Textured objects were encouraged.

At 12 months B.W. demonstrated some active elbow flexion, but it was not full range. Her mother was instructed to put her at a tabletop level with her chest to provide support for the entire arm so the elbow could flex and extend without working against gravity. Periods in the elastic harness were continued about half of her waking day.

At 17 months B.W. was observed spontaneously using the arm for assisted holding, and when an object was placed in her hand she would hold it. The absence of active intrinsic or extrinsic extensors prevented release of objects and led to persistent long flexor tightness. Wrist extension was still not present. Splinting with a custom-made neo-

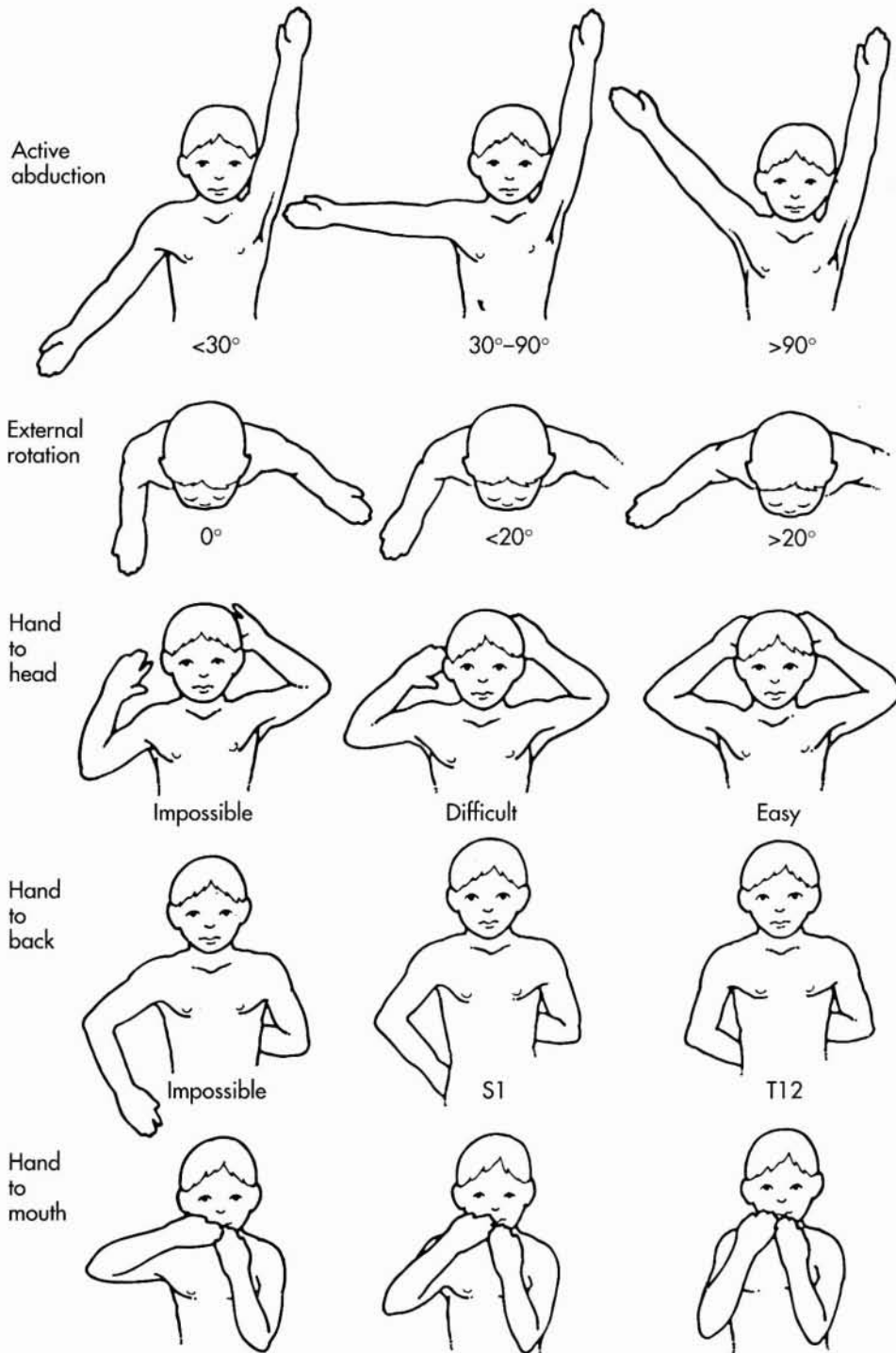


Fig. 25-13. Mallet's method of functional assessment of the shoulder. (From Hentz VR: Operative nerve repair of the brachial plexus in infants and children. In Gelberman RH, ed: *Operative nerve repair and reconstruction*, New York, 1991, Lippincott.)

prene splint with a reinforcement of thermoplastic material gave the needed support to keep the wrist out of flexion, but did not rigidly immobilize it (see Fig. 25-10). Supporting the wrist increased the spontaneous use of the palmar surface of the hand.

At 3 years she spontaneously uses the hand as an assist but cannot oppose thumb and fingertips because of the position of extreme wrist flexion (see Fig. 25-9). With a rigid wrist support, she spontaneously holds objects in her hand (see Fig. 25-11). She demonstrates about 90° of elbow

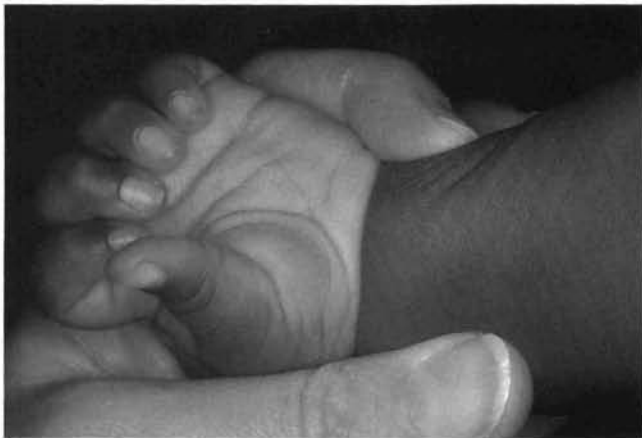

Fig. 25-14. Tightness of the finger flexor muscles is common when the wrist and finger extensors are absent.



Fig. 25-15. Full elbow flexion is accomplished by assistance from the uninjured arm.

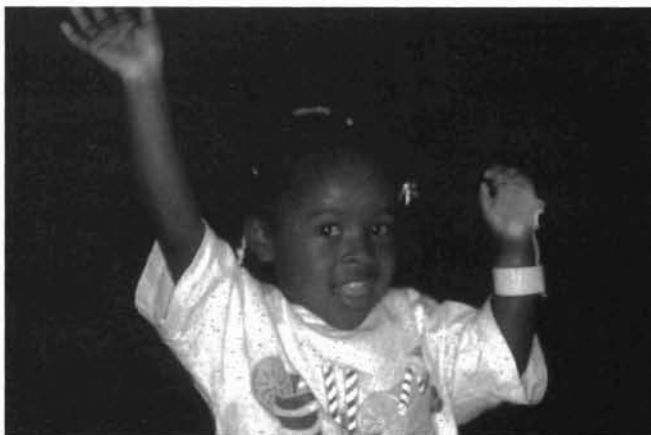

Fig. 25-16. Demonstration of limited shoulder flexion and abduction at 3 years of age.

flexion but is unable to touch her nose with her involved hand. She spontaneously brings the elbow into full flexion by assisting with the other hand when asked to touch her nose (Fig. 25-15). When reaching for the ceiling her abduction is limited to 75° (Fig. 25-16).

B.W.'s clinical picture at 3 years demonstrates the anticipated prognosis that absence of elbow flexion at 3 months means less than full return. She will likely always have limited active motion and strength in the elbow and shoulder. The extrinsic imbalance in her wrist may later be improved with a tendon transfer for wrist extension, but the likelihood of intrinsic motor return in the hand is slim.

Therapy for B.W. has consisted of parental instruction and splinting for maintenance of joint motion and periodic instructions about activities to facilitate returning function.

CONCLUSION

The pioneering work of Narakas in neurotization techniques for lesions previously thought inoperable²⁰ will undoubtedly be developed to a level where parents of children with brachial plexus lesions can look forward to an even more positive prognosis than at any time in the past. The current practice of surgical treatment of OBP is developing rapidly as progress is being made in microneural reconstruction.¹² Therapists in the future will have the exciting experience of working with children and parents during the return of function once previously thought to be unattainable. The skills needed by the therapist will not change. Keen observation and practical instructions for the parents will always be required to assist the child with returning muscle function and sensibility.

REFERENCES

1. Beatty JH: Paralytic conditions. In Crenshaw AH, ed: *Campbell's operative orthopedics*, St Louis, 1992, Mosby.
2. Boome RS, Kaye JC: Obstetric traction injuries of the brachial plexus, *J Bone Joint Surg* 1988; 70(B):571-576.
3. Brown KLB: Review of obstetrical palsies: nonoperative treatment. In Terzis JK, ed: *Microreconstruction of nerve injuries*, Philadelphia, 1987, Saunders.
4. Danyau M: Paralysie du membre supérieur, chez le nouveau-né, *Bull Soc Chir* 1851; 2:148.
5. Duchenne GBA: *De l'électrisation localisée et de son application à la pathologie et à la thérapeutique*, ed 3, Paris, 1872, JB Ballière.
6. Eng GD, Koch B, Smokvina MD: Brachial plexus palsy in neonates and children, *Arch Phys Med Rehabil* 1978; 59:458.
7. Erb W: Über eine eigenthümliche Localisation von Lähmungen im plexus brachialis, *Verhandl Naturhist-Med (Heidelberg)* 1874; 2:130.
8. Gilbert A, Hentz VR, Tassin J-L: Brachial plexus reconstruction in obstetric palsy: operative indications and postoperative results. In Urbaniak JR, ed: *Microsurgery for major limb reconstruction*, St Louis, 1987, Mosby.
9. Gilbert A, Whitaker I: Obstetrical brachial plexus lesions, *J Hand Surg* 1991; 16(B):489-491.
10. Gilbert A, Tassin J-L: Obstetrical palsy: a clinical, pathologic, and surgical review. In Terzis JK, ed: *Microreconstruction of nerve injuries*, Philadelphia, 1987, Saunders.

11. Greenwald AG, Schute PC, Shiveley JL: Brachial plexus birth palsy: a 10-year report on the incidence and prognosis, *J Pediatr Orthop* 1984; 4(6).
12. Hentz VR: Microneural reconstruction of the brachial plexus. In Green DP, ed: *Operative hand surgery*, ed 3, New York, 1993, Churchill Livingstone.
13. Hentz VR: Operative nerve repair of the brachial plexus in infants and children. In Gelberman RH, ed: *Operative nerve repair and reconstruction*, New York, 1991, Lippincott.
14. Hentz VR, Meyer RD: Brachial plexus microsurgery in children, *Microsurg* 1991; 12:175-185.
15. Hoffer MH: Assessment and natural history of brachial plexus injury in children. In Gelberman RH, ed: *Operative nerve repair and reconstruction*, New York, 1991, Lippincott.
16. Jepson PN: Obstetrical paralysis, *Ann Surg* 1930; 91:724-730.
17. Klumpke A: Contribution à l'étude des paralysies radiculaires du plexus brachial, *Rev Méd* 1885; 5:591.
18. Leffert RD: Brachial plexus. In Green DP, ed: *Operative hand surgery*, ed 3, New York, 1993, Churchill Livingstone.
19. Leffert RD: *Brachial plexus injuries*, New York, 1985, Churchill Livingstone.
20. Narakas AO: Thoughts on neurotization or nerve transfers in irreparable nerve lesions. In Terzis JA, ed: *Microreconstruction of nerve injuries*, Philadelphia, 1987, Saunders.
21. Mallet J: Paralysie obstétricale du plexus brachial: traitement des séquelles, *Rev Clin Orthop* 1972; 58(suppl 1):166.
22. Meyer RD: Treatment of adult and obstetrical brachial plexus injuries, *Orthopaedics* 1986; 9:899-903.
23. Piatt JH, Hudson AR, Hoffman HJ: Preliminary experiences with brachial plexus exploration on children: birth injury and vehicular trauma, *Neurosurg* 1988; 22(4):715-723.
24. Scaglietti O: The obstetrical shoulder trauma, *Surg Gyn Obstet* 1938; 66:868-877.
25. Smellie W: *A collection of cases and observations in midwifery*, vol 2, ed 4, London, 1786.
26. Sunderland S: *Nerve and nerve injuries*, ed 2, New York, 1978, Churchill Livingstone.
27. Terzis JK, Liberson WT, Levine R: Obstetrical brachial plexus palsy. In Jabaley ME, Williams HB, eds: *Peripheral nerve surgery*, Philadelphia, 1986, Saunders.